2024 MAGNIMS–CMSC–NAIMS consensus recommendations on the use of MRI for the diagnosis of multiple sclerosis

Frederik Barkhof, Daniel S Reich*, Jiwon Oh, Maria A Rocca, David K B Li, Pascal Sati, Christina J Azevedo, Francesca Bagnato, Peter A Calabresi, Olga Ciccarelli, Michael G Dwyer, Gabriele C DeLuca, Nicola De Stefano, Christian Enzinger, Massimo Filippi, Cristina Granziera, June Halper, Roland G Henry, Claudio Gasperini, Susan Gauthier, Ludwig Kappos, Cornelia Laule, Scott D Newsome, Xavier Montalban, Sarah A Morrow, Menno M Schoonheim, Nancy Sicotte, Ahmed Toosy, Jeffrey Wilken, Tarek Yousry, Jaume Sastre-Garriga, Anthony Traboulsee*, Daniel Ontaneda*, Àlex Rovira* on behalf of the Magnetic Resonance Imaging Network in Multiple Sclerosis, the Consortium of Multiple Sclerosis Centers, and North American Imaging in Multiple Sclerosis Cooperative MRI guidelines working group†*

Lancet Neurol 2025; 24: 866–79

See **Comment** page 808

See **Position Paper** page 850 and **Personal View** page 880

*Contributed equally

†Members listed in the appendix (p 1)

Department of Radiology and Nuclear Medicine, Amsterdam UMC, Vrije Universiteit, Amsterdam, Netherlands (Prof F Barkhof MD); **Queen Square Institute of Neurology** (Prof F Barkhof, Prof O Ciccarelli MD), **Hawkes Institute** (Prof F Barkhof), **University College London, UK; Translational Neuroradiology Section, National Institute of Neurological Disorders and Stroke, National Institutes of Health, Bethesda, MD, USA** (Prof D S Reich MD); **Division of Neurology, Department of Medicine, St Michael's Hospital, University of Toronto, Toronto, ON, Canada** (J Oh MD); **Departments of Radiology and Medicine (Neurology), University of British Columbia, Vancouver, BC, Canada** (Prof D K B Li MD); **Department of Neurology, Cedars-Sinai Medical Center, Los Angeles, CA, USA** (P Sati PhD, N Sicotte MD); **Department of Neurology, Keck School of Medicine, University of Southern California, Los Angeles, CA, USA** (C J Azevedo MD); **Neurology Department, Nashville Veteran Affairs Medical Center, Nashville, TN, USA** (F Bagnato MD); **Neuroimaging Unit, Neuroimmunology Division, Neurology Department, Vanderbilt University Medical Center, Nashville, TN, USA** (F Bagnato); **Department of Neurology, Johns Hopkins University School of Medicine, Baltimore, MD, USA** (Prof P A Calabresi MD, S D Newsome MD); **Queen**

MRI plays an increasingly important role in the diagnosis of multiple sclerosis. We discuss the expanded role of MRI in the 2024 McDonald diagnostic criteria for multiple sclerosis, which include the optic nerve as a fifth anatomical location, in addition to the periventricular, juxtacortical or cortical, infratentorial, and spinal cord regions. The diagnosis of multiple sclerosis can now be confirmed when the criteria of dissemination in space are fulfilled with the detection of typical lesions in at least four locations without additional evidence. We recommend appropriate imaging strategies and MRI acquisition protocols for all aspects of multiple sclerosis diagnosis, including fat-saturated sequences for detection of symptomatic optic nerve lesions. Diagnostic imaging should always cover the brain and spinal cord and include susceptibility-sensitive sequences for the assessment of the central vein sign and paramagnetic rim lesions, which can be especially helpful in cases when conventional imaging findings are insufficient to establish a diagnosis. We discuss how to handle the diagnosis of radiologically isolated presentations of multiple sclerosis, which are included in the 2024 criteria. We present recommendations for image interpretation and avoidance of misdiagnosis, and extend the recommendations to the use of MRI in the diagnosis of multiple sclerosis in older people, children, people with vascular comorbidities or migraine, and people living outside Europe and North America. Finally, we provide recommendations for standardisation of MRI acquisition and communication of results to enable an earlier diagnosis while maintaining high diagnostic specificity.

Introduction

Since 2001, the diagnosis of multiple sclerosis has increasingly relied on the use of MRI, a trend that continues with the 2024 McDonald diagnostic criteria.[1] In the 2010 version of the criteria,[2] spinal cord lesions were introduced as a relevant anatomical feature, together with infratentorial, juxtacortical, and periventricular lesions. The 2017 revisions relaxed the dissemination in space (DIS) criteria by dropping the need for lesions to be asymptomatic and included cortical lesions as an alternative for juxtacortical involvement. However, optic nerve lesions remained excluded, despite optic neuritis being a frequent mode of presentation.[3] In the 2024 revision,[1] the optic nerve is now included as a fifth anatomical location. Optic nerve involvement can be shown with the use of optical coherence tomography and visual evoked potentials, as discussed in a companion paper,[4] but also with the use of MRI. Several other important MRI-related changes have been implemented, including use of pathologically specific markers of multiple sclerosis observed on susceptibility-sensitive imaging (ie, the central vein sign [CVS] and paramagnetic rim lesions [PRL]). It is now also possible to diagnose multiple sclerosis in people with symptoms not specific for multiple sclerosis and in individuals without symptoms in whom lesions suggestive of multiple sclerosis are incidentally discovered—the so-called radiologically isolated syndrome (RIS).

Since the 2024 McDonald diagnostic criteria involve major changes to MRI findings, reconsidering the existing guidelines for MRI[5] in the diagnostic setting is needed. Appropriate use of MRI becomes key to obtaining the earliest possible diagnosis and avoiding misdiagnosis,[6] including differentiation from myelin oligodendrocyte glycoprotein antibody disease (MOGAD) and aquaporin-4 antibody-positive neuromyelitis optica spectrum disorder (AQP4+NMOSD).

The 2024 McDonald criteria are presented in a Position Paper by Montalban and colleagues.[1] In this Personal View, we provide practical recommendations for imaging strategies and acquisition MRI protocols for all aspects of multiple sclerosis diagnosis (including sequences for the detection of optic nerve lesions and susceptibility-sensitive sequences for the assessment of the CVS and PRL), image interpretation, avoidance of misdiagnosis, standardisation of MRI acquisition, and communication of results.

Methods

Representatives of the Magnetic Resonance Imaging Network in Multiple Sclerosis (MAGNIMS), North American Imaging in Multiple Sclerosis Cooperative (NAIMS), and Consortium of Multiple Sclerosis Centers (CMSC) networks discussed updated guidance over a series of meetings on the best imaging strategy, acquisition protocols, image interpretation, and radiological reporting strategies for multiple sclerosis diagnosis. The core writing group (FB, DSR, MR, DL, JG, AT, DO, and ÀR) made proposals that were reviewed

by all authors; open issues were resolved by consensus in a meeting including all members.

The use of MRI in the 2024 McDonald diagnostic criteria for multiple sclerosis

In the 2024 McDonald diagnostic criteria,[1] typical lesions with DIS are the cornerstone of the diagnosis. A key (and often the first) diagnostic step remains the exclusion of better alternative explanations for clinical or imaging findings. Multiple sclerosis can now be diagnosed when MRI lesions are demonstrated in at least four typical anatomical locations without further evidence in patients with attack or progression onset. In cases with lesions in fewer anatomical locations, a diagnosis of multiple sclerosis requires demonstration of dissemination in time (DIT; ie, presence of enhancing and non-enhancing lesions on a single scan or accumulation of new lesions on subsequent MRI), lesions that are highly specific for multiple sclerosis on MRI (ie, presenting the CVS or having a paramagnetic rim), or CSF findings. The additional information needed for a diagnosis of multiple sclerosis in case of lesions in fewer than four MRI typical anatomical locations, depends on the number of these locations affected (table 1).

Recommended imaging strategy

The recommendations in this Personal View are designed for use in both clinical and research settings. We recognise that some methods (particularly susceptibility-sensitive imaging) might not yet be widely available. Optimisation of clinical protocols and radiologist training to achieve sufficient confidence for image interpretation might be required.

In patients with the suspicion of multiple sclerosis, we recommend imaging the brain and the whole spinal cord to reach a diagnosis, exclude other diagnoses, inform prognosis, and serve as a reference for comparisons with follow-up imaging. This initial examination should include administration of intravenous gadolinium-based contrast agents for detection of enhancing lesions and evaluation of differential diagnoses. The detection of concomitant contrast-enhancing and non-enhancing lesions allows the fulfilment of the DIT criteria. Imaging of the spinal cord at the time of diagnosis should be done routinely, not only because the spinal cord is an anatomical location for DIS but also because spinal cord lesions have important prognostic value.

Spinal cord MRI is particularly important for individuals with spinal cord symptoms to confirm the presence of a demyelinating lesion and rule out other potential causes. Spinal cord MRI is also valuable in adults older than 50 years and people with cerebrovascular pathology, as age-related or vascular white matter abnormalities that mimic multiple sclerosis are rarely associated with spinal cord lesions.[7] Beyond increasing sensitivity and specificity of multiple sclerosis diagnosis, the presence of spinal cord lesions portends a poor prognosis and might thus inform treatment decisions. Finally, should an indication for spinal cord imaging arise during follow-up, it is helpful to have an initial examination to enable the assessment of any new lesions.

Optic nerve MRI is recommended if there is an initial presentation of optic neuritis, especially if other sources of objective confirmation (ie, optical coherence tomography and visual evoked potentials) are not available or equivocal. Demonstrating a typical demyelinating lesion in the optic nerve will confirm the clinical suspicion of optic neuritis. Such a lesion can be used to show one of the five anatomical locations for DIS, even in individuals without a clinical history of optic neuritis. An optic nerve lesion, if it is new or enhances with gadolinium-based contrast agents, can also be used to fulfil the criteria for DIT (figure 1). Optic nerve MRI is optional in non-optic neuritis cases, as the diagnostic yield of finding asymptomatic lesions is low.

In cases when no gadolinium-enhancing lesions on the initial examination are present and no evidence from the CSF or demonstration of the CVS are available, repeated imaging should be considered to demonstrate DIT (table 1). Repeat brain imaging can be done without gadolinium-based contrast agents administration, as new T2-weighted fluid-attenuated inversion recovery (FLAIR) lesions will suffice to show DIT. The chances of finding isolated new spinal cord lesions (ie, without associated new brain lesions) are low,[8] and therefore repeat spinal cord imaging is not routinely recommended.

Susceptibility-sensitive imaging is now recommended for routine use to show the presence of lesions with the

	Relapse or progressive onset	RIS and other non-specific presentations
Four or five	No further evidence needed	Any one of: DIT*, CSF†, or CVS‡
Two or three	Any one of: DIT, CSF, or CVS	Any one of: DIT, CSF, or CVS
One	Combination of the following: DIT or CSF; and CVS or PRL§. In patients with progression from onset (≥12 months), at least two spinal cord lesions and any one of: DIT, CSF, or CVS	Not able to make diagnosis
0	Not able to make diagnosis	Not able to make diagnosis

CVS=central vein sign. DIT=dissemination in time. PRL=paramagnetic rim lesion. RIS=radiologically isolated syndrome. *Second clinical attack or simultaneous presence of gadolinium-enhancing and non-enhancing lesions at any time or a new T2-hyperintense or gadolinium-enhancing lesion on follow-up MRI. †Positive for oligoclonal bands or kappa free-light chains. ‡Select 6 is considered positive when six or more white matter lesions are CVS positive; if fewer than ten white matter lesions are detected on MRI, the number of CVS positive lesions should be the majority. §Presence of at least one lesion with a paramagnetic rim.

Table 1: **Requirements for a diagnosis of multiple sclerosis depending on the number of anatomical locations affected**

Square MS Centre, Department of Neuroinflammation, Queen Square Institute of Neurology, London, UK (Prof O Ciccarelli, Prof A Toosy PhD); **National Institute for Health and Care Research University College London Hospitals Biomedical Research Centre, London, UK** (Prof O Ciccarelli); **Department of Neurology, Jacobs School of Medicine, State University of New York at Buffalo, Buffalo, NY, USA** (M G Dwyer PhD); **Nuffield Department of Clinical Neurosciences, University of Oxford, Oxford, UK** (Prof G C DeLuca MD); **Department of Medicine, Surgery and Neuroscience, University of Siena, Siena, Italy** (Prof N De Stefano MD); **Department of Neurology, Medical University of Graz, Graz, Austria** (C Enzinger MD); **Neurology Unit** (Prof M Filippi, M Rocca MD), **IRCCS San Raffaele Scientific Institute, Milan, Italy; Vita-Salute San Raffaele University, Milan, Italy** (Prof M Filippi, M Rocca); **Department of Neurology, University Hospital and University of Basel, Basel, Switzerland** (Prof C Granziera MD, Prof L Kappos MD); **Research Center for Clinical Neuroimmunology and Neuroscience Basel, University Hospital, University of Basel, Basel, Switzerland** (Prof C Granziera, Prof L Kappos); **Translational Imaging in Neurology Basel, Department of Biomedical Engineering, Faculty of Medicine, University Hospital Basel and University of Basel, Basel, Switzerland** (Prof C Granziera, Prof L Kappos); **Consortium of MS Centers, Hackensack, NJ, USA** (J Halper MSN††); **Departments of Neurology, Radiology and Biomedical Imaging, Weill Institute for Neurosciences, University of California, San Francisco, CA, USA** (Prof R G Henry PhD); **Department of Neuroscience, S Camillo Forlanini Hospital, Rome, Italy** (C Gasperini MD); **Department of Neurology, Weill Cornell Medicine, New York, NY, USA** (S Gauthier DO); **Departments of Radiology, Pathology & Laboratory Medicine, Physics & Astronomy, International Collaboration on Repair Discoveries, University of**

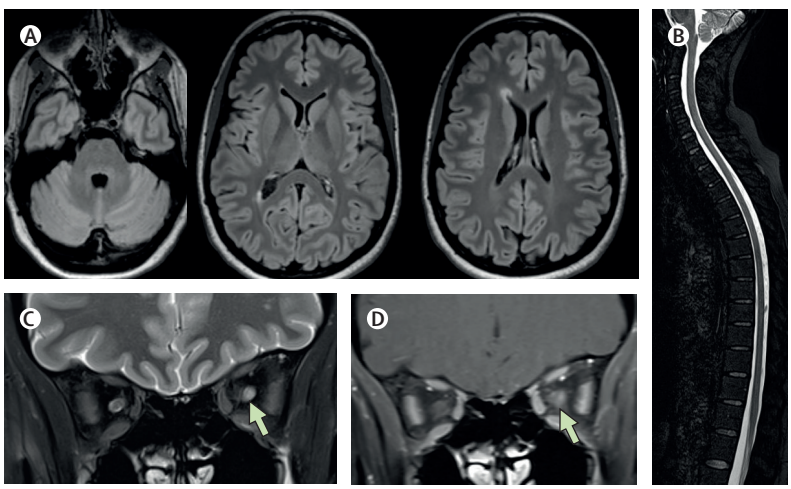

Figure 1: **Case study to illustrate the value of optic nerve imaging**
A previously healthy woman aged 33 years presented with left-sided optic neuritis. (A) Brain MRI (axial 3D T2-FLAIR) showed multiple periventricular lesions but no cortical or juxtacortical lesions or infratentorial lesions. (B) Since spinal cord imaging (STIR sequence) was also unremarkable, a diagnosis of multiple sclerosis would not have been possible according to the 2017 McDonald diagnostic criteria. Orbital imaging showed increased signal in the left optic nerve (C) on coronal fat-suppressed T2-weighted, (D) with enhancement after gadolinium administration. Collectively, these images show evidence of dissemination in space (two of five anatomical locations) and dissemination in time (enhancing and non-enhancing lesions), allowing a diagnosis of multiple sclerosis to be made according to the revised 2024 criteria.

British Columbia, Vancouver, BC, Canada (C Laule PhD); **Multiple Sclerosis Centre of Catalonia and Department of Neurology Hospital Universitari Vall d'Hebron, Universitat Autònoma de Barcelona, Barcelona, Spain** (Prof X Montalban MD, J Sastre-Garriga MD); **Department of Neurology, Universitat de Vic/Central de Catalunya ,Barcelona, Spain** (Prof X Montalban, J Sastre-Garriga); **Department of Clinical Neurosciences, University of Calgary, Hotchkiss Brain Institute, Calgary, AB, Canada** (S A Morrow MD); **MS Center Amsterdam, Anatomy and Neurosciences, Vrije Universiteit Amsterdam** (M M Schoonheim PhD), **Amsterdam Neuroscience, Amsterdam UMC, Amsterdam, Netherlands** (M M Schoonheim, Prof F Barkhof); **Institute of Neurology, Faculty of Brain Sciences, University College London, London, UK** (Prof A Toosy); **Department of Neurology, Georgetown University, Washington, DC, USA** (J Wilken PhD); **Washington Neuropsychology Research Group, USA** (J Wilken); **Lysholm Department of**

CVS.[9] Identifying CVS might eliminate the need for a CSF examination or follow-up scanning to establish DIT if the initial scan does not reveal both enhancing and non-enhancing lesions. We recognise that routinely performing susceptibility-sensitive imaging might not be feasible on all scanners, but whenever possible acquisition should be included in the initial diagnostic protocol to avoid repeat scanning. Additional sequences specifically designed for PRL detection remain optional given that they are less relevant for diagnosis (table 1), although PRL also have prognostic relevance. On many scanners, phase images can be reconstructed from the same sequences used for CVS detection, allowing for PRL detection. It is important to note that demonstration of CVS or PRL is not required to make a diagnosis of multiple sclerosis.

Guidelines for standardised MRI protocols for the brain, optic nerve, and spinal cord

The recommended MRI protocol for clinical use in the diagnosis of multiple sclerosis includes the core set of sequences that is minimally required for the diagnostic investigation and serves as a reference for comparison with follow-up examinations.[5] These sequences will generally fit within the clinical workflow for scanner time and radiologist review (table 2).

MRI systems with commonly available field strength (ie, 1·5 Tesla [T] or 3 T) should provide adequate signal–to–noise ratio and in-plane resolution (pixel size) of maximum 1×1 mm. Consistent repositioning of axial slices along the subcallosal line (or, alternatively, the anterior–posterior commissure) and image registration are essential for detecting changes in follow-up imaging (eg, new T2 lesions). 3D acquisitions with isotropic voxels (equal ≤1 mm dimensions) allow for a good realignment with previous scans. Older scanners should acquire contiguous 2D slices with maximum thickness of 3 mm.

The core MRI protocol of the brain includes the following sequences: T2-weighted FLAIR sequences (preferably acquired in 3D) for identification of lesions; axial T2-weighted sequences (with single or dual echo) for identification or confirmation of posterior fossa lesions; susceptibility-sensitive sequences for CVS identification that can also be used, if phase images are saved, for PRL identification; and mildly T1-weighted sequences after the injection of a standard dose (usually 0·1 mmol/kg bodyweight) of gadolinium-based contrast agents. Given that multiple sclerosis lesions are rarely spontaneously T1-hyperintense, routinely acquiring pre-contrast T1-weighted sequences is not needed. After gadolinium-based contrast agents injection, a minimum delay of 5 min (which might be used to acquire FLAIR and susceptibility-sensitive sequences) is needed before obtaining T1-weighted sequences. Macrocyclic gadolinium-based contrast agents are strongly preferred due to less risk of gadolinium deposition, lessening the need to check renal function. Gadolinium-based contrast agents administration is considered safe during breastfeeding but should be avoided in pregnancy unless clinically essential.[10,11]

CVS can be detected on various gradient-echo MRI sequences, providing that there is sufficient susceptibility (or T2*) weighting and maximum 1·0 mm isotropic spatial resolution. One highly efficient approach uses 3D segmented echo-planar imaging, which is now available on several commercial platforms.[12] Voxel-wise multiplication of 3D segmented echo-planar imaging and T2-FLAIR images allows identification of both vein and lesion in a single image termed FLAIR*[13], which simplifies reading images for CVS.[14] Gradient-echo sequences to detect CVS can also be used with susceptibility-weighted image processing.[15] In case T2 lesions appear isointense or hypointense on susceptibility-sensitive images, arithmetic combination or superimposition of T2-FLAIR and susceptibility-weighted images are recommended for accurate CVS detection. A meta-analysis has shown increased CVS detection at higher field strengths (ie, 3·0 and 7·0 T) compared with lower field strengths (ie, 1·5 T).[16] Administration of gadolinium-based contrast agents immediately before or during acquisition of susceptibility-sensitive sequences improves detection of the CVS[17] and is especially recommended at 1·5 T.[18]

Other potentially useful brain 3D sequences include double inversion recovery (DIR),[19] phase-sensitive inversion recovery (PSIR),[20] or heavily T1-weighted gradient-echo (eg, magnetisation-prepared rapid gradient

	Brain	Spinal cord	Optic nerve
Field strength	≥ 1·5 T	≥ 1·5 T†	≥ 1·5 T
Acquisition	3D preferred	2D or 3D	2D or 3D
Slice thickness	3D: 1 mm isotropic;‡ 2D: ≤ 3 mm, no gap§	Sagittal ≤ 3 mm, no gap; axial ≤ 5 mm, no gap	≤ 2–3 mm, no gap
In-plane resolution	≤ 1 mm × 1 mm	≤ 1 mm × 1 mm	≤ 1 mm x 1 mm
Coverage	Whole brain¶	Whole cord‖	Optic nerves and optic chiasm
Axial scan orientation	Subcallosal or anterior–posterior commissure plane††	Perpendicular to sagittal axis of spinal cord	Align to optic nerve and optic chiasm orientation
Core sequences	3D T2 FLAIR; axial T2-weighted (single or dual echo) 3D T2* gradient-recalled-echo (echo-planar imaging or optimised SWI)‡‡ for CVS; and post-gadolinium-based contrast agent axial mildly T1-weighted‡‡	Two complementary sagittal sequences (ie, T2-weighted, proton density, short tau inversion recovery, PSIR, or MP[2]RAGE); axial 2D T2-weighted spin echo/gradient echo (or multiplanar reconstruction from MPRAGE) at least covering the cervical segment; post-gadolinium-based contrast agent sagittal moderately T1-weighted; §§ note: do not use FLAIR or myelographic sequences (very heavily T2-weighted, eg, CISS)	Coronal fat suppressed T2-weighted or short tau inversion recovery; post-gadolinium-based contrast agent coronal fat suppressed T1-weighted
Additional sequences	3D T2* gradient-recalled-echo (3D-echo-planar imaging or SWI) for PRL;¶¶ DWI for ischaemia; DIR or PSIR;‖‖ and high-resolution 3D heavily T1-weighted	Post-gadolinium-based contrast agent axial moderately T1-weighted through lesions	Axial FS T2 or short tau inversion recovery and post-gadolinium-based contrast agent T1-weighted; 3D DIR (whole brain and optic nerve coverage)

CISS=constructive interference in steady state. CVS=central vein sign. DIR=double-inversion recovery. DWI=diffusion-weighted imaging. FLAIR=fluid-attenuated inversion recovery. MPRAGE=magnetisation-prepared rapid acquisition gradient echo. MP2RAGE=magnetisation prepared 2 rapid acquisition gradient echoes. SWI=susceptibility-weighted imaging. PRL=paramagnetic rim lesions. PSIR=phase sensitive inversion recovery. 3D=3 dimensional. 2D=2 dimensional. †No added value of 3 T compared with 1·5 T for spinal cord imaging. ‡Isotropic preferred, if over-contiguous (through-plane and in-plane) then not more than 1·5 mm with 0·75 mm overlap. §Diffusion-weighted imaging: slice thickness should be at least 5 mm with no more than a 10–30% slice gap. ¶Include as much of the cervical cord as possible. ‖Cervical and thoracolumbar spinal cord, including conus. ††2D acquisition (prescribed) or 3D reconstruction (reformatted) for axial oblique slice. ‡‡ Reconstructed as sagittal and axial. §§The 3D gradient-recalled echo should have sufficient T2* weighting and resolution to detect central veins and a low flip angle to ensure lesions are visible. If SWI post-processing is used, enhanced magnitude images are optimal for CVS detection. FLAIR* postprocessing can null high signal in CSF for better conspicuity of lesions. Filtered phase or quantitative susceptibility mapping postprocessing of the same acquired images allows detection of PRL and is recommended to avoid subsequent rescanning. The CVS is best detected at field strengths of at least 3 T but can also be seen at 1·5 T, especially when scanned after gadolinium-based contrast agent administration. For details see appendix (pp 5, 6, 10). ¶¶0·1 mmol/kg bodyweight gadolinium-based contrast agent. Ensure an at least 5 min delay. Additional gadolinium-based contrast agent is not needed if cord imaging follows brain imaging. ‖‖If not already performed. Filtered phase or quantitative susceptibility mapping images are necessary for PRL detection. A low flip angle is not required but can help with lesion detection on accompanying magnitude or enhanced magnitude images. PRL are best detected at field strengths of at least 3 T but can also be seen at 1·5 T. Gadolinium-based contrast agent is not required (appendix p 5). DIR or PSIR use for cortical lesion detection.

Table 2: **Standardised MRI protocol parameters**

Neuroradiology, University College London Hospitals, National Hospital for Neurology and Neurosurgery, Neuroradiological Academic Unit, University College London, Institute of Neurology, London, UK (Prof T Yousry MD)**; Department of Medicine (Neurology), University of British Columbia, Vancouver, BC, Canada** (Prof A Traboulsee MD)**; Mellen Center for Multiple Sclerosis, Department of Neurology, Cleveland Clinic Lerner College of Medicine of Case Western Reserve University, Cleveland, OH, USA** (Prof D Ontaneda MD)**; Section of Neuroradiology, Department of Radiology, Hospital Universitari Vall d'Hebron, Universitat Autònoma de Barcelona, Barcelona, Spain** (À Rovira MD)

Correspondence to:
Prof Frederik Barkhof, Department of Radiology and Nuclear Medicine, Amsterdam UMC, Vrije Universiteit, Amsterdam, Netherlands
f.barkhof@amsterdamumc.nl

††Dr Halper died

See **Online** for appendix

For more on **safety administration of contrast** see https://www.esur.org/esur-guidelines-on-contrast-agents/

echo)[21] for identifying cortical lesions and monitoring brain volume changes, and diffusion-weighted imaging, which can identify acute ischaemia as a differential diagnosis. However, diffusion-weighted imaging might not be specific, as acute multiple sclerosis lesions can also show diffusion restriction as detected in acute ischaemia.[22]

Full spinal cord coverage (cervical to conus) is recommended with field strength of at least 1·5 T, slice thickness of 3 mm, and in-plane resolution of maximum 1×1 mm. Spinal cord imaging is technically demanding, requiring multi-array coils and prevertebral saturation slabs. Two complementary sagittal sequences (any combination of: T2 fast-spin-echo, proton density, short tau inversion recovery, and 3D inversion-prepared T1) are essential to distinguish small multiple sclerosis lesions from artifact, with axial slices at least through the cervical region with moderately T2-weighted spin-echo or T2* gradient echo.[23] FLAIR and heavily T2-weighted sequences (ie, sequences used for MRI myelography) should be avoided for spinal lesion detection. No additional gadolinium-based contrast agents administration is required if the spinal cord imaging is done immediately after gadolinium-based contrast agents-enhanced brain imaging, and moderately T1-weighted sequences are recommended to demonstrate gadolinium-based contrast agents-enhancing lesions.

Optic nerve MRI sequences, required if there is an initial presentation of optic neuritis, include at minimum coronal fat-suppressed T2-weighted or short tau inversion recovery sequences. When gadolinium-based contrast agents are given in cases of acute optic neuritis, post-gadolinium-based contrast agents coronal fat-suppressed T1-weighted sequences are recommended. Coverage should include the optic nerve and the optic chiasm, with coronal planes oriented perpendicular to the optic nerve. When axial images are added, they should align with the optic nerve and chiasm. In-plane resolution should be maximum 1×1 mm, with slices of thickness of maximum 2–3 mm and no gap. For improved lesion detection, additional sequences, such as 3D-DIR, can be incorporated, which might increase sensitivity particularly for asymptomatic lesions.[24–26]

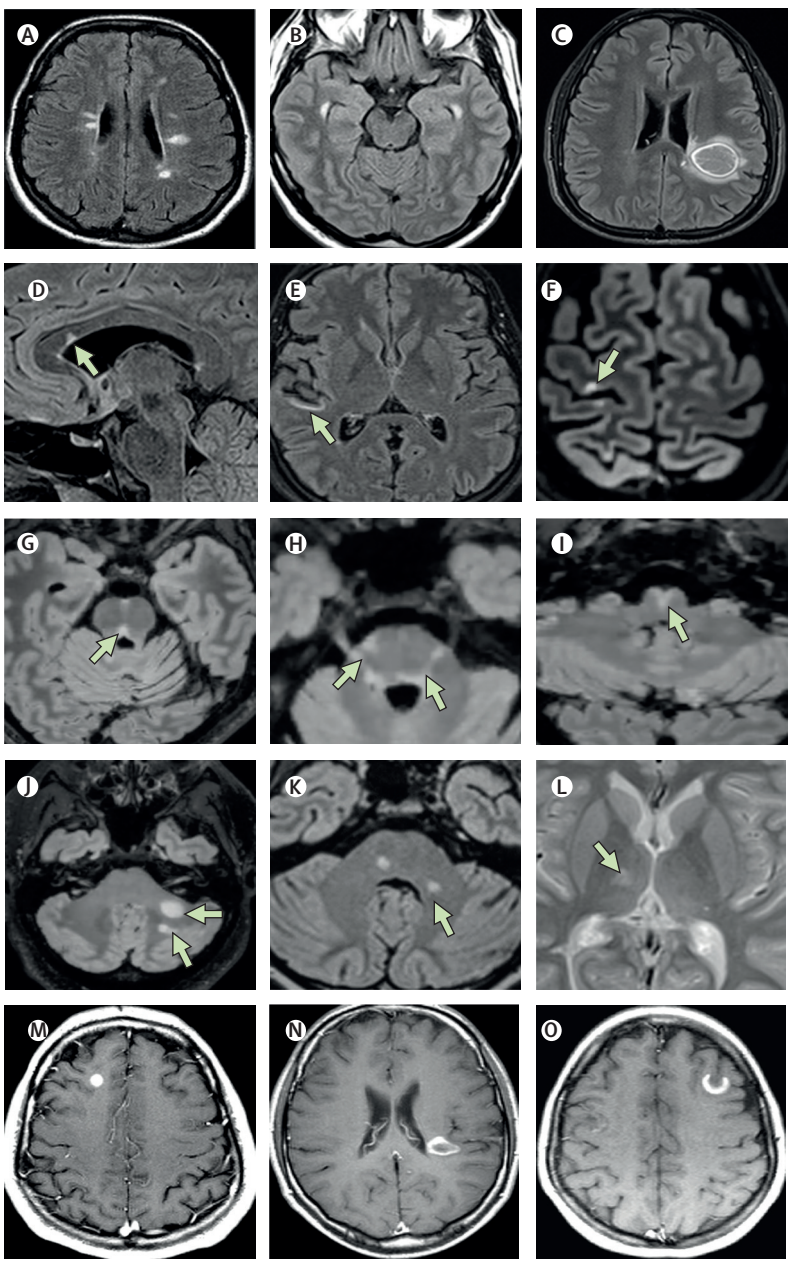

(Figure 2 continues on next page)

Guidelines for the interpretation of MRI findings

The most usual source of misdiagnosis of multiple sclerosis is misinterpretation of MRI findings.[27] Given the increasing reliance on MRI, in this section, we define the relevant imaging characteristics of MRI lesions in multiple sclerosis to help avoid misinterpretation.[28]

MRI characteristics of typical brain multiple sclerosis lesions and their diagnostic use

Brain multiple sclerosis lesions asymmetrically affect the white matter of the cerebral hemispheres, the brainstem, and the cerebellum, and involve the cortical and deep grey matter (mainly the thalamus; figure 2, appendix [pp 2–4]).[29,30] Typically lesions are smaller than 1 cm in diameter, although larger lesions can also occur.[31] Lesions should generally be at least 3 mm in longest diameter. However, the required length of lesions depends on the location. For example, lesions of less than 3 mm located at the floor of the fourth ventricle, the outer margin of the pons, or in the corpus callosum can be considered demyelinating.[29,32] Lesions smaller than 3 mm, rounded, deep in the white matter, especially in basal frontal areas and not demonstrating CVS, are non-specific (appendix p 9). Perivenular lesions might be ovoid in shape in the axial plane (Dawson's fingers), with their long axis perpendicular to the lateral ventricles.[33]

Periventricular lesions are in direct contact with the lateral ventricles, without intervening normal appearing white matter. Periventricular lesions include corpus callosum lesions that abut the ventricles. However, lesions that abut the lateral ventricles but are in the deep grey matter (eg, thalamus) are not considered periventricular.

Juxtacortical or cortical lesions with typical morphology are a hallmark feature of multiple sclerosis and are rarely encountered in other conditions.[29,34] Juxtacortical lesions affect the U-fibres, which are typically not affected in ischaemia. Cortical lesions that do not involve juxtacortical white matter are difficult to identify on conventional MRI, even at 3 T.[19] 3D sequences such as DIR, PSIR, or MPRAGE can improve their visualisation.[20,21]

Infratentorial lesions involve the brainstem, cerebellar peduncles, and cerebellum. They preferentially affect the floor of the fourth ventricle, surface of the pons, intrapontine trigeminal tracts, middle and superior cerebellar peduncles, periaqueductal grey matter, cerebellar white matter and cortex, and medullary pyramids.[35]

Deep white matter lesions are common in multiple sclerosis, but given their low specificity, the deep white matter is not considered as one of the characteristic anatomical locations within the diagnostic criteria for demonstrating DIS. Such lesions can, however, contribute to the diagnosis when they are gadolinium-based contrast agents-enhancing (which signifies DIT), harbour a CVS, or have a paramagnetic rim.

Gadolinium-based contrast agents enhancement in active multiple sclerosis lesions is a transient feature (median duration <4 weeks) that rarely persists beyond 2–3 months.[36] Lesions with enhancement for longer than 3 months should prompt consideration of an alternative diagnosis (eg, capillary telangiectasia). Enhancing lesions have a nodular or ring-like pattern; the ring can be partly open.[37] Large enhancing lesions sometimes have a pseudotumoural appearance, indicating the presence of mass effect (displacement) on nearby structures. The pattern of gadolinium-based contrast agents

enhancement also depends on lesion age and timing after gadolinium-based contrast agents injection.[38]

Finding non-enhancing and enhancing lesions on any scan indicates DIT. Finding new T2 lesions at any time during follow-up imaging also indicates DIT. New lesions should meet the size and other criteria discussed in this section, and care should be taken that they are not an artifact due to changes in MRI protocol or slice positioning. New T2 lesions do not necessarily have to be in the anatomical locations described for the fulfilment of the DIS criteria. When new T2 lesions are only found in the deep white matter, they ideally should be ovoid, involve specific regions such as the corpus callosum or temporal lobe,[39] have a CVS, or be a paramagnetic rim, particularly in patients older than 50 years or with vascular risk factors.

Characteristics of the CVS and its use in the diagnosis of multiple sclerosis

The CVS identifies the perivenous distribution of multiple sclerosis lesions and can be detected with susceptibility-sensitive MRI sequences.[40] The CVS is found in most multiple sclerosis lesions and is present early in the disease, including in clinically isolated syndrome (CIS),[41] RIS,[42] and in paediatric multiple sclerosis.[43] Conversely, white matter lesions in common radiological mimickers of multiple sclerosis, including cerebral small vessel disease, AQP4+NMOSD, and migraine, rarely show the presence of a central vein.[44]

The CVS is defined as a thin (<2 mm diameter) hypointense line or dot, present in two perpendicular planes and running partially or entirely through the centre of a lesion (figure 2P, appendix p 10).[45] The CVS should not be assessed in lesions of less than 3 mm in size, confluent lesions that contain multiple veins, or where veins are poorly visible(panel). Submillimetre isotropic acquisition is helpful for multiplanar visualisation of even the smallest lesions.[45]

An optimal cutoff of at least 40–46% CVS-positive lesions best differentiates multiple sclerosis from common mimickers in meta-analysis studies.[16,47] Assessing the presence of the CVS in only a subset of lesions is recommended for efficiency of interpretation. The Select 6 method is considered positive when six or more white matter lesions are CVS positive; if fewer than ten white matter lesions are detected on MRI, the number of CVS positive lesions should be the majority. Select 6 shows good sensitivity and excellent specificity for multiple sclerosis.[48] In RIS, 95% of patients studied fulfilled the Select 6 rule.[48]

The 2024 McDonald diagnostic criteria for multiple sclerosis incorporate the Select 6 rule as a highly specific method that can support a multiple sclerosis diagnosis in several scenarios: DIS with two or three anatomical locations, a single anatomical location in combination with either positive CSF or DIT, and in RIS with at least two anatomical locations (table 1). The Select 6 rule was incorporated as it was deemed feasible in clinical practice while retaining high specificity. Given the high prevalence of CVS-positive lesions in multiple sclerosis, most patients with DIS (ie, lesions in at least two anatomical locations) meet the Select 6 rule, which can be used in place of CSF positivity or DIT on initial MRI scan to make the diagnosis. On the other hand, it should be noted that the diagnostic criteria do not require assessment of CVS criteria; the diagnosis of

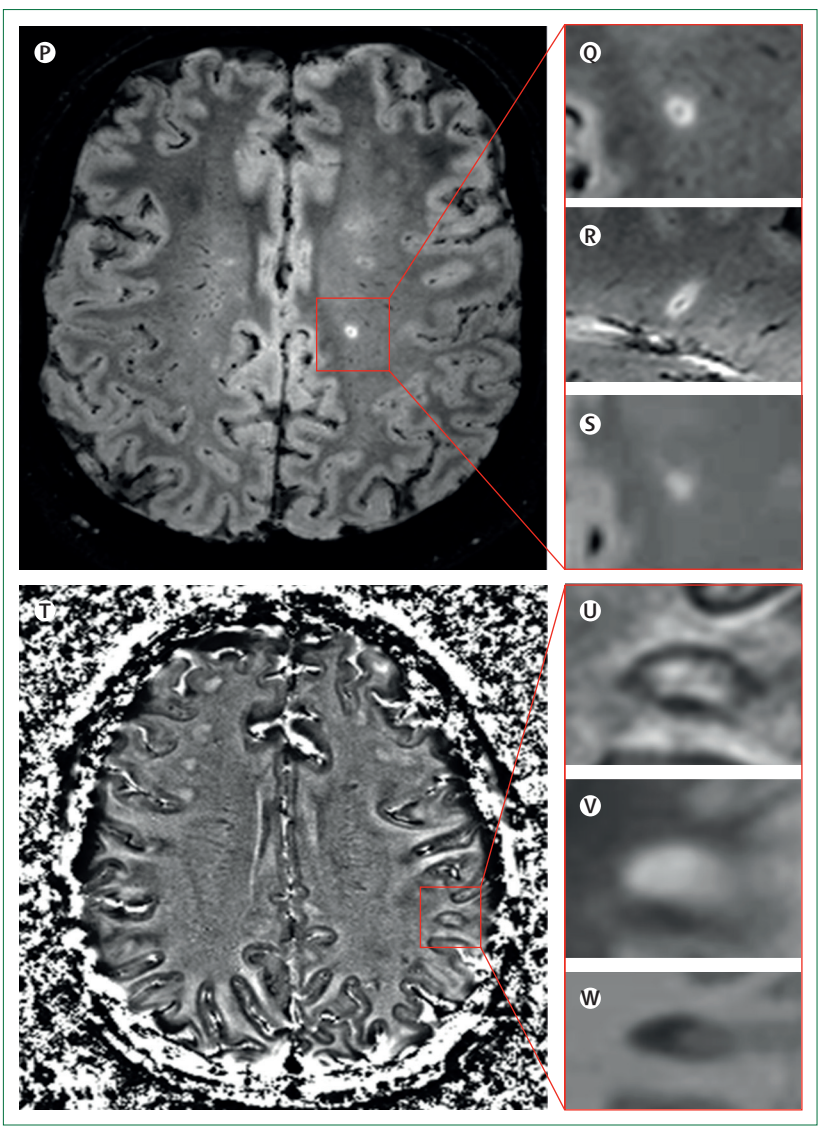

Figure 2: **Examples of brain MRI lesions in patients with multiple sclerosis**
(A) Periventricular and typical ovoid shaped. (B) Periventricular anterior temporal lobe. (C) Pseudotumoural. (D) Callosal-septal (arrow). (E) Juxtacortical (arrow). (F) Intracortical (arrow). (G) Periaqueductal (arrow). (H) Periphery of the pons and floor of the fourth ventricle (arrows). (I) Pyramids (arrow). (J) Deep white matter in the cerebellar hemisphere (arrow). (K) Middle cerebellar peduncle (arrow). (L) Thalamus (arrow). (M) Nodular enhancement. (N) Ring enhancement. (O) Open-ring enhancement. (P, Q) Central vein sign positive lesion on axial 3D segmented echo-planar imaging fluid-attenuated inversion recovery (FLAIR*) (yellow square). (R) Sagittal 3D segmented echo-planar imaging FLAIR* and (S) corresponding axial native FLAIR. (T, U) Paramagnetic rim lesion on axial 3D segmented echo-planar imaging phase image (yellow square). (V) Axial FLAIR and (W) axial post-gadolinium-based contrast agent T1-weighted images (no enhancement detected).

Panel: **Definition of central vein sign and paramagnetic rim lesions**

Central vein sign (CVS)[45]

- Detected using magnitude susceptibility-sensitive images
- Appears as a single thin (<2 mm) hypointense line or small hypointense dot
- Can be visualised in at least two perpendicular MRI planes, and appears as a thin line or dot in at least one plane
- Runs partly or entirely through the lesion
- Is positioned centrally in the lesion (that is, located approximately equidistant from the lesion's edges and passing through the edge at no more than two places), regardless of the lesion's shape
- Exclusion criteria: lesion is <3 mm in diameter in all planes; lesion merges with another lesion (confluent lesions); lesion has multiple distinct veins; or lesion is poorly visible (owing to motion or other MRI-related artefacts)

Paramagnetic rim lesions[46]

- Detected using phase susceptibility-sensitive images
- A discrete rim with paramagnetic properties that is continuous around at least two-thirds of the outer edge of the white matter portion of the lesion (excluding any cortical or ependymal border), on the slice of maximum visibility
- The rim colocalises with the edge of all or part of a lesion core that is hyperintense on T2-weighted images; in case of large T2-lesions, detection of the paramagnetic rim lesion core can be facilitated by also looking at a more discernible hypointense core on T1-weighted images
- The rim (or part of it) is discernible on at least two consecutive slices (2D acquisition) or in two orthogonal planes (3D acquisition)
- The core of the lesion colocalises with all or part of a T2-hyperintense lesion that does not enhance on T1-weighted post-gadolinium-based contrast agent images*
- Exclusion criteria: veins running alongside the rim that might resemble a rim. Red flags and cautions: small paramagnetic or diamagnetic structures (eg, iron-laden ferritin or hemosiderin dots, veins, and myelin debris); lesions showing magnetic dipole artefacts (often best seen in coronal or sagittal reformations); and anatomical regions with susceptibility artefacts (much of the anterior temporal lobes, orbitofrontal cortices, and infratentorial brain)

*If post-gadolinium-based contrast agent MRI is not available, a paramagnetic rim lesion should only be defined as such when the corresponding lesion was already present on a T2-weighted scan acquired at least 3 months before. If both post-gadolinium-based contrast agent MRI and a previous scan are not available, a paramagnetic rim lesion should be marked as possible, and its chronicity should be confirmed with a scan acquired at least 3 months later.

multiple sclerosis can be established even if the Select 6 rule is not met. However, given the data on CVS prevalence, we urge caution in diagnosing multiple sclerosis if only a minority of lesions are CVS positive. A recommended MRI protocol for CVS detection is provided in table 2 and the appendix (pp 5–6, 10–12).

Characteristics of paramagnetic rim lesions and their use in the diagnosis of multiple sclerosis

PRL are a distinctive feature of multiple sclerosis (figure 2T–X, appendix pp 11, 12, table 3), reflecting iron-containing microglia surrounding chronic-active white matter lesions, and portend poor prognosis.[49] They are highly specific to multiple sclerosis.[50] The formation of the paramagnetic rim occurs within months after lesion inception, with larger lesions and lesions appearing in older individuals more likely to be a paramagnetic rim.[51] PRL have also been documented in cases of paediatric-onset multiple sclerosis,[52] and in individuals with RIS.[53] Once established, PRL tend to persist, with an estimated half-life of 7–10 years.[54] Detection of PRL is most efficient using high-field MRI scanners, particularly at 3 T, although they are also discernible at 1·5 T.[55]

Susceptibility-sensitivity imaging for PRL necessitates the use of gradient-echo pulse sequences, with phase images being recommended alongside magnitude or phase-enhanced magnitude images. Variants of susceptibility-sensitive imaging, as a standard product sequence on major MRI platforms, can detect PRL. Nevertheless, saving phase images alongside susceptibility-weighted imaging-type reconstructions, which combine magnitude and phase images, is advised. We provide a recommended MRI protocol for PRL detection (appendix pp 5–6, 11–12).

For diagnostic purposes, only unequivocal PRL should be considered,[46] as defined in the panel. Despite evidence for the specificity of PRL,[50,56] considering that the experience of neuroradiologists in identifying such lesions is not yet widespread, their inclusion in the 2024 criteria is limited to an adjunctive role, in combination with CSF findings or DIT, when lesions in only a single anatomical location are present. PRL are not required to be in one of the typical anatomical locations of the DIS criteria, and PRL in the deep white matter, which are relatively common,[56] can be considered.

MRI characteristics of optic nerve lesions and differentiation from other diseases

Although optic neuritis is usually diagnosed clinically, imaging of the optic nerve can be valuable to rule out alternative diagnoses and inform about the severity of optic nerve damage. Optic nerve imaging is particularly relevant when the clinical presentation deviates from typical multiple sclerosis-related presentations, such as absence of pain, severe visual loss, simultaneous

Location	Multiple sclerosis	AQP4+NMOSD	MOGAD
Optic nerve	Unilateral involvement (bilateral in <5%); short lesions; anterior involvement (intraorbital and intracanalicular segments); optic nerve swelling at lesion site frequent in the acute phase; optic disc swelling or enhancement extremely rare; and perineuritis extremely rare	Simultaneous bilateral involvement (15–35% of patients); longitudinally extensive (more than 50% of the optic nerve length); posterior involvement (mainly the intracranial segment); optic nerve swelling at lesion site very frequent in the acute phase; optic disc swelling or enhancement infrequent; and perineuritis extremely rare	Simultaneous bilateral involvement (30–60% of cases); longitudinally extensive (>50% of the optic nerve length); anterior involvement (intraorbital segment) with variable extension to other optic nerve segments (intracanalicular, intracranial); optic nerve swelling at lesion site frequent in the acute phase; optic disc swelling or enhancement (20–50% of cases); and perineuritis with orbital fat stranding (50% of cases)
Optic chiasm	Rarely involved	Occasional (20%), usually isolated	Occasional (15% of patients) and often as a result of extension of a longitudinally extensive optic nerve lesion
Associated brain lesions	Common and with typical multiple sclerosis features (50% of patients)	Frequent, rarely showing multiple sclerosis-typical features	Normal brain MRI in approximately 50% of cases, rarely showing multiple sclerosis-typical features

AQP4+NMOSD=aquaporin-4 antibody positive neuromyelitis optica spectrum disorder. MOGAD=myelin oligodendrocyte glycoprotein antibody-associated disease.

Table 3: **Characteristic MRI features of the anterior optical pathways that differentiate multiple sclerosis, AQP4+NMOSD, and MOGAD**

bilateral involvement, progression of visual loss or pain beyond 2 weeks, or insufficient recovery after three weeks.[57]

Imaging of the optic nerves in acute and subacute optic neuritis typically reveals increased T2-weighted signal intensity, often accompanied by swelling, particularly when done within 3 weeks of onset. These MRI features, which reflect demyelination and inflammation, can be observed in more than 90% of people with acute optic neuritis. MRI lesions in multiple sclerosis-related optic neuritis typically involve a unilateral short segment of the optic nerve (<50% of the optic nerve length).[58] Optic nerve MRI lesions primarily affect the intracanalicular and intraorbital segments but rarely involve the intracranial segment or the optic chiasm. The presence of longitudinally extensive lesions, chiasmal involvement, or perineuritis should raise suspicion of alternative diagnoses, such as AQP4+NMOSD or MOGAD.

More sensitive MRI sequences than conventional fat-saturated T2-weighted or STIR sequences might enhance the detection of demyelinating lesions in the optic nerves. 3D-DIR seems particularly effective, showing high sensitivity and specificity in identifying both acute and chronic optic nerve inflammatory demyelinating lesions in individuals with a history of acute or previous episodes of optic neuritis.[24,25] Additionally, 3D-DIR can detect optic nerve signal abnormalities in approximately 40% of individuals with multiple sclerosis who have no previous clinical history of optic neuritis.[25,59,60] However, 3D-DIR cannot be considered as a core sequence in the MRI protocol for optic nerve imaging as it is not universally available.

Gadolinium-based contrast agents-enhanced fat-suppressed T1-weighted images are useful in evaluating multiple sclerosis-related acute optic neuritis cases. The pattern and extent of enhancement can help suggest alternative diagnoses, such as AQP4+NMOSD or MOGAD, and non-inflammatory conditions like extrinsic or compressive lesions.[61] We provide an overview of the characteristic MRI findings in the anterior optical pathway that help differentiate between multiple sclerosis, AQP4+NMOSD, and MOGAD (table 3, appendix p 13).

Characteristics of MRI spinal cord lesions and differentiation from other diseases

Spinal cord lesions in multiple sclerosis are hyperintense on proton density, T2-weighted, T2*-weighted, and STIR mages and hypointense on heavily T1-weighted images such as MPRAGE and PSIR. Spinal cord lesions can occur at any level and usually span less than one vertebral segment on sagittal images. Multiple short-segment lesions are typical of multiple sclerosis and do not occur in normal ageing or people with cerebrovascular disease.[7] Multiple sclerosis cord lesions are typically sharply demarcated and can have associated localised spinal cord volume loss. However, acute inflammatory lesions can also be ill-defined and have mild localised mass effect. By contrast, active lesions in AQP4+NMOSD and MOGAD tend to be longitudinally extensive (>3 vertebral segments) and are ill-defined with associated mass effect. Involvement of the conus is suggestive of MOGAD (table 3).

On axial T2-weighted and T2*-weighted images, multiple sclerosis spinal cord lesions are often round or wedge-shaped, involve the peripheral white matter, and might extend into the central grey matter. By contrast, lesions in AQP4+NMOSD and MOGAD are located centrally in the cord, spare the peripheral white matter, and might even be limited to the central grey matter—the so-called H-sign[62] seen especially in MOGAD in the acute phase. In AQP4+NMOSD, there might be cyst-like components, referred to as bright spotty lesions.[63]

Gadolinium-based contrast agents enhancement of active spinal cord multiple sclerosis lesions can appear nodular or ring-like. AQP4+NMOSD lesions can show an elongated ring-like enhancement in the sagittal plane. MOGAD lesions can have ring-like or patchy enhancement. In the acute phase, enhancement is less frequent in MOGAD than in AQP4+NMOSD or

multiple sclerosis.[62] Enhancement in spondylotic spinal cord compression can be persistent and limited to a horizontal band throughout the spinal cord (pancake sign)[64] or at the periphery of one side of the spinal cord (croissant sign).[65] In neurosarcoidosis, enhancement might extend longitudinally, mostly affects the pia and adjacent spinal cord tissue, and can invade the posterior sulcus, which is best seen on axial images (trident sign).[66] Neurosarcoid-related enhancement might persist for several months.

For the fulfilment of the 2024 McDonald diagnostic criteria for multiple sclerosis, finding at least one typical short-segment lesion is sufficient to contribute to DIS (and DIT in case of an enhancing lesion). In individuals with a progressive onset, DIS can be met without lesions in other anatomical locations when at least two spinal cord lesions are present.[1] Not finding spinal cord lesions should trigger consideration of alternative diagnoses, especially in older patients and individuals with cardiovascular risk factors.

MRI diagnostic considerations in specific situations

The use of MRI findings in the diagnosis of multiple sclerosis requires special consideration in late-onset multiple sclerosis (defined as clinical onset at age >50 years),[67] people with vascular and other comorbidities (eg, hypertension, hypercholesterolemia, diabetes, and obesity), people with migraine, in paediatric-onset multiple sclerosis (POMS), and in individuals living outside Europe or North America.

Late-onset multiple sclerosis, vascular comorbidities, and migraine

Deep and some periventricular white matter lesions are frequent with normal ageing, vascular comorbidities, and migraine.[68–71] Thus, detecting at least three periventricular lesions in patients with CIS aged 45 years or older improves specificity of multiple sclerosis diagnosis, preserving accuracy and slightly reducing sensitivity, compared with a single periventricular lesion.[72,73] Cortical lesions, common in multiple sclerosis, have not been observed in migraine.[71,74] In older individuals with vascular risk factors, peripheral pontine lesions make multiple sclerosis more likely than central pontine lesions.[75] Incidental T2-hyperintense lesions are exceedingly rare in the spinal cord.

The proportion of CVS-positive lesions in people with multiple sclerosis decreases with age and vascular comorbidities, particularly hypertension. However, the presence of more than 40% of lesions that are CVS positive correctly identifies nearly all people with multiple sclerosis, and the Select 6 rule remains valid even in older individuals.[76] Additional studies evaluating the diagnostic performance of PRL in older people with multiple sclerosis, migraine, and vascular comorbidities are needed, and PRL have not been reported in healthy ageing.[56]

POMS

Based on the good performance of previous McDonald diagnostic criteria for multiple sclerosis in POMS, the 2024 criteria adopt a common framework for adult and paediatric multiple sclerosis. Early studies of CVS and PRL in small POMS cohorts have reported variable results,[43,52,77] indicating the need for additional research. No study has evaluated the performance of the Select 6 rule in POMS, hence a conservative threshold of at least 50% of lesions positive for the CVS is recommended when CVS is assessed for diagnosis. Having at least 40% CVS lesions was associated with a greater likelihood to develop disability progression over the subsequent 5 years and a higher relapse rate.[78] Few studies have evaluated the presence of PRL in POMS.[52,79,80] Based on these studies, the majority of POMS have at least one PRL, which is 100% specific for POMS versus other immune-mediated acquired demyelinating syndromes.

Populations outside North America and Europe

In Latin America and Asia, AQP4+NMOSD is more prevalent than multiple sclerosis, compared with prevalences in Europe and North America,[76] so atypical radiological features should prompt antibody testing. There are few studies evaluating the performance of the CVS and PRL outside Europe and North America. However, scarce data suggest that the CVS has similar diagnostic performance to what has been observed in Europe and North America.[82,83]

Prognostic relevance of MRI findings in multiple sclerosis beyond diagnostic purposes

Although the focus of our recommendations is on multiple sclerosis diagnosis, initial MRI examinations can also guide prognosis and serve as a reference for monitoring future disease activity. Several features on the initial brain MRI provide prognostic indicators of long-term disability. Unfavourable findings include: a large number (>20) and volume of T2-weighted lesions; the presence of brainstem, cortical,[84] or spinal cord lesions; multiple gadolinium-based contrast agents-enhancing lesions; reduced whole brain volume or ventricular expansion; and regional brain atrophy (eg, corpus callosum, thalamus, or brainstem).[73,85–87] Lesion features that portend a poor prognosis include hypointensity on mildly T1-weighted images,[88] presence of PRL, and a high proportion of lesions with the CVS. Several studies show that the presence of at least four PRL is associated with greater disability.[89,90] The presence of spinal cord lesions and tissue loss are strong predictors of long-term disability accrual[88,91,92] and can occur in the absence of clinical manifestations.

Short-term follow-up MRI also carries major prognostic value. The occurrence of new lesions, specifically in

some anatomical locations (ie, spinal cord and brainstem) strongly predicts long-term disability.[93] These data are supported by the finding that early new lesion development in the spinal cord and brainstem is associated with increased risk of worse disease course 15 years after the diagnosis in people with CIS.[92] The presence of gadolinium-based contrast agents-enhancing lesions early in the disease is associated with increased relapse rates over time but only weakly with disability accrual over the short term.[94] However, the presence of new enhancing lesions in the first years after CIS presentation is a strong predictor of long-term disability accrual at 15 years.[92] Brain volume loss early in the disease course is associated with long-term accumulation of disability in people with relapsing-remitting multiple sclerosis.[95,96] Even in RIS, brain atrophy can be present[97] and might serve as a prognostic marker; however, larger studies to document the association of brain volume loss and clinical outcomes in RIS are needed. Finally, MRI is also a useful tool for disease monitoring of treatment, and the initial diagnostic brain and spinal cord imaging can be used as a reference to monitor the development of active lesions and possibly also brain volume.[98–100]

Recommendations for a standardised and structured radiological diagnostic reporting and for the communication of MRI findings

The use of template-driven structured MRI reports for multiple sclerosis can streamline the radiological reporting process, ensure consistency, and enhance communication between radiologists and referring physicians.[101,102] A good communication between referring practitioners and reporting radiologists is crucial for accurate diagnosis.

We recommend that key information is included in the MRI requisition form completed by the referring practitioner and incorporated in the radiology report completed by the radiologist (appendix pp 7, 8). To aid in the radiological interpretation and diagnostic reporting, the clinical question and the purpose of the MRI requested by the referring practitioner should be clearly stated on the request form. Gadolinium-basedcontrast agents should be requested for the initial MRI, whereas follow-up scans for diagnostic purposes can be done without gadolinium-based contrast agents (as new T2-FLAIR lesions suffice to show DIT).

The radiology report (appendix pp 7, 8) should describe lesions with respect to number, location, size, and morphology. Universal nomenclature should be used, for example lesions are best described as periventricular or deep white matter rather than subcortical. The conclusion of the radiology report should define whether the MRI findings fulfil radiological aspects of the diagnostic criteria. The report should also include a recommendation regarding possible follow-up brain MRI imaging to establish DIT or assess additional MRI features not assessed at initial imaging. Finally, the report should include a general interpretation of the MRI findings as being typical or atypical for multiple sclerosis.

Automated quantitative tools that provide the location, volume and number of (new) lesions, and global and regional brain volume quantification contextualised relative to normative reference populations can potentially improve the accuracy and objectivity of MRI assessments. These tools are now commercially available; however, their usefulness and benefit will require more extensive real world clinical validation and in-use evaluation.[103]

Search strategy and selection criteria

References for this Personal View were identified by reviewing our personal files and through searches of PubMed for articles published in English between Sept 1, 2021 and Feb 1, 2025, with the terms "multiple sclerosis OR MS", "guidelines", diagnosis", and "magnetic resonance imaging OR MRI". We reviewed reference lists of relevant articles and the articles for additional references. The final reference list was generated based on originality, recency, and relevance to the scope of this Personal View.

Conclusions and future directions

In the 2024 McDonald criteria for the diagnosis of multiple sclerosis, MRI plays an increasingly important role, allowing for an earlier and more specific diagnosis of multiple sclerosis than former diagnostic criteria. Optic nerve imaging plays a crucial role, serving as a fifth anatomical location for DIS. Multiple sclerosis can now be diagnosed without further evidence when DIS is shown in at least four anatomical locations and in people with RIS, making it even more important to appropriately interpret MRI scans and recognise atypical features. With the addition of new imaging criteria, such as CVS and PRL—although not necessary in many cases—radiologists, neuroradiologists, and neurologists will need to familiarise themselves with their definitions and characteristic imaging features. The diagnostic value of CVS and PRL in paediatric populations and outside North America and Europe remains to be fully established through further study. We expect that sequences and postprocessing optimised for the detection of the CVS will soon be more widely available. Further work is needed to understand the value of ultra-high field (eg, 7 T) as well as ultra-low field (eg, 0·064 T) in the diagnosis of multiple sclerosis.[104] With the great number of MRI features contributing to a diagnosis of multiple sclerosis in the 2024 revisions, it will be important to concisely report and communicate MRI results, allowing their integration with clinical and other paraclinical findings.

Contributors

FBar, DSR, JO, ATr, DO, and ÀR participated in in meetings for discussions and reaching consensus, all prepared the initial draft of

manuscript, reviewed the draft manuscript, and approved the manuscript. MAR, DKBL, PS, CJA, FBag, PAC, OC, MGD, DA, NDS, CE, MF, CG, JH, RGH, CG, SG, LK, CL, SDN, XM, SM, MS, NS, ATo, JW, TY, JS-G, and ATr participated in in meetings for discussion and reaching consensus, reviewed the draft manuscript, and approved the manuscript.

Declaration of interests

FBar is supported by European Commission, Medical Research Council, NIHR Biomedical Research Centre at University College London Hospitals, GE Healthcare, Roche, and Alzheimer's Disease Data Initiative (paid to institution); is a consultant for Combinostics, IXICO, and Roche; and participates in Steering Committees or Data safety Monitoring Boards for EISAI, Biogen, Prothena, and Merck. DSR is supported by the Intramural Research Program of the National Institute of Neurological Disorders and Stroke, US National Institutes of Health (NIH); and he has received research support from Abata Therapeutics and Sanofi. JO holds the Waugh Family Chair in MS Research at St Michael's Hospital, University of Toronto; has received grant funding from MS Canada, Brain Canada, the National MS Society, Biogen-Idec, Roche, and EMD-Serono; and has received personal compensation for consulting or speaking from Biogen-Idec, BMS, EMD-Serono, Eli Lilly, Horizon Therapeutics, Novartis, Roche, and Sanofi-Genzyme. MAR received consulting fees from Biogen, Bristol Myers Squibb, Eli Lilly, Janssen, and Roche; received speaker honoraria from AstraZeneca, Biogen, Bristol Myers Squibb, Bromatech, Celgene, Genzyme, Horizon Therapeutics Italy, Merck Serono SpA, Novartis, Roche, Sanofi, and Teva; and declares research support from the MS Society of Canada, the Italian Ministry of Health, the Italian Ministry of University and Research, and Fondazione Italiana Sclerosi Multipla. DKBL is Emeritus Director of the UBC MS/MRI Research Group, which has received grant support for investigator-initiated studies from Genzyme and Roche; and has given lectures, supported by non-restricted education grants from Academy of Health Care Learning, Biogen, Novartis, Consortium of MS Centers, and Sanofi-Genzyme. PS receives research support from the National Institutes of Health, the National Multiple Sclerosis Society, the Department of Defense, and the Erwin Rautenberg Foundation. CJA receives grant support from the National MS Society, the National Institutes of Health, and the Keck School of Medicine; has received consulting honoraria for participation in advisory boards, data safety monitoring committee from MRI Adjudication Committee for Horizon Therapeutics, TG Therapeutics, EMD Serono, Genentech, and Zenas Biopharma; and for participation in educational events for Sanofi Genzyme, MJH Life Sciences, Efficient, and Spire Learning. FBag is supported by the National Institute of Health, The VA Healthcare Administration, the National MS Society and the Voros Innovation and Impact Funds; is a consultant for Sanofi; and participates in Steering Committee and Advisory Boards for Merck-Serono and Sanofi. PAC has received grant funding from the NIH, National Multiple Sclerosis Society, US Department of Defense, Genentech, and the Myelin Repair Foundation; and has received consulting honoraria for serving on scientific advisory boards for Novartis, Idorsia, and Elli Lilly. OC has received grant funding from National Institute for Health and Care Research, UK MS Society, Medical Research Council, and Rosetrees Trust; and has received personal compensation for consulting or speaking from Novartis, Roche, and Biogen. MGD received grant support from Novartis, Bristol Myers Squibb, Mapi Pharma, and Merck Serono; and declares consulting fees from Bristol Myers Squibb and Mapi Pharma. GCD has received research funding from the Oxford Biomedical Research Centre, Medical Research Council (UK), National Health and Medical Research Council, UK MS Society, Department of Defense, Oxford-Quinnipiac-Trinity Health Of New England Partnership, Rosetrees Trust, and the Multiple sclerosis Research, Treatment, and Education; and has received honoraria for consulting or speaking for Novartis, Merck, the MS Academy, American Academy of Neurology, and the Wellcome Trust. NDS has received honoraria from Biogen, Celgene (Bristol Myers Squibb), EMD Serono, Genzyme, Immunic, Novartis, Roche, and Teva for consulting services, speaking, and travel support; serves on advisory boards for Biogen, Genzyme, Immunic (the healthcare business of Merck), Darmstadt, Germany, Novartis, and Roche; has received research grant support from the Italian MS Society; and is co-founder of Siena Imaging. CE has received funding for travel and speaker honoraria from Biogen, Bayer, Celgene, Merck, Novartis, Roche, Shire, Genzyme and Teva Pharmaceutical Industries/Sanofi-Aventis; received research support from Merck Serono, Biogen, and Teva Pharmaceutical Industries/Aanofi-Aventis; and has served on scientific advisory boards for Bayer, Biogen, Celgene, Merck, Novartis, Roche, and Teva Pharmaceutical Industries/Sanofi-Aventis. MF received compensation for consulting services from Alexion, Almirall, Biogen, Merck, Novartis, Roche, and Sanofi; declares speaking activities from Bayer, Biogen, Celgene, Chiesi Italia SpA, Eli Lilly, Genzyme, Janssen, Merck-Serono, Neopharmed Gentili, Novartis, Novo Nordisk, Roche, Sanofi, Takeda, and TEVA; participation in Advisory Boards for Alexion, Biogen, Bristol-Myers Squibb, Merck, Novartis, Roche, Sanofi, Sanofi-Aventis, Sanofi-Genzyme, and Takeda; scientific direction of educational events for Biogen, Merck, Roche, Celgene, Bristol-Myers Squibb, Lilly, Novartis, and Sanofi-Genzyme; and receives research support from Biogen, Merck-Serono, Novartis, Roche, the Italian Ministry of Health, the Italian Ministry of University and Research, and Fondazione Italiana Sclerosi Multipla. CGo is supported by the Swiss National Science Foundationgrant (PP00P3_176984), the Stiftung zur Förderung der gastroenterologischen und allgemeinen klinischen Forschung, University Hospital Basel, and the Research Center for Clinical neuroimmunology and Neuroscience; the employers of Cristina Granziera have received the fees (used exclusively for research support) from Siemens, GeNeuro, Genzyme-Sanofi, Biogen, Novartis, and Hoffmann La Roche; the employers of Cristina Granziera also have received advisory board and consultancy fees from Actelion, Genzyme-Sanofi, Novartis, GeNeuro, Merck, Biogen, and Hoffmann La Roche, as well as speaker fees from Genzyme-Sanofi, Novartis, GeNeuro, Merck, Biogen, and Hoffmann La Roche. RGH has received consulting fees from Roche, Novartis, QIA Consulting, Sanofi, and Boston Pharma; and research funding from Roche, Genentech, and Atara. CGa has received fees as a speaker or as an advisory board member from Almirall, Biogen, Merck, Roche, Novartis, Sandoz, AstraZeneca, Viatris, Sanofi, Jansen, and Bristol Myers Squibb. SG has received grant funding from the National Institutes of Health, National Multiple Sclerosis Society, and Genentech; and has received consulting fees from Contineum Therapeutics and Kiniksa Pharmaceuticals. LK received research support to the institution (University Hospital Basel, Basel, Switzerland) including steering committee, advisory board, and consultancy fees from Actelion (Janssen), Bayer, Biogen, Bristol Myers Squibb, GSK, Janssen, Japan Tobacco, Merck, Novartis, Roche, Sanofi, Santhera, and Shionogi, and TG Therapeutics; speaker fees from Bayer, Biogen, Merck, Novartis, Roche, and Sanofi; support of educational activities from Allergan, Bayer, Biogen, CSL Behring, Desitin, Merck, Novartis, Pfizer, Roche, Sanofi, Shire, and Teva; license fees for Neurostatus platform access; and grants from Bayer, Biogen, EU, InnoSwiss, Merck, Novartis, Roche, Swiss Multiple Sclerosis Society, and Swiss National Research Foundation. CL reports funding support from the Natural Sciences and Engineering Research Council of Canada, the Craig H. Neilsen Foundation, the International Collaboration on Repair Discoveries, and the University of British Columbia. SDN reports grants or contracts from Biogen, Roche, Genentech, Lunbeck, Sanofi, National Multiple Sclerosis Society, Department of Defense, and Patient Centered Outcomes Research Institute; personal compensation for consulting from Biogen, Roche, Genentech, Bristol Myers Squibb, Novartis, and TG Therapeutics; is the study lead PI for a Roche clinical trial program; and reports research support from the Stiff Person Syndrome Research Foundation. XM's institution has received compensation for lecture honoraria and travel expenses, participation in scientific meetings, clinical trial steering committee membership, or clinical advisory board participation in recent years from Abbvie, Actelion, Alexion, Bial PD, Biogen, Bristol-Myers Squibb/Celgene, EMD Serono, Genzyme, Hoffmann-La Roche, Immunic Therapeutics, Janssen Pharmaceuticals, Medday, Merck, Mylan, Nervgen, Neuraxpharm, Novartis, Peervoice, Samsung-Biosys, Sandoz, Sanofi-Genzyme, Teva Pharmaceutical, TG Therapeutics, Excemed, Medscape, European Committee for Treatment and Research in Multiple Sclerosis, Multiple Sclerosis International Federation, and National Multiple Sclerosis Society or any of their affiliates. In the last 3 years, SAM has served as an advisory board member or received consulting fees from Biogen Idec, BMS/Celgene, EMD Serono, Novartis, Roche, and Sanofi Genzyme; participated in a

speaker's bureau for Biogen Idec, BMS/Celgene, EMD Serono, Novartis, Roche, and Sanofi; has received research support from Biogen Idec EMD Serono, Novartis, Roche, Sanofi Genzyme, MS Canada, Canadian Institute of Health Research, and National Multiple Sclerosis Society; has participated as a site investigator in clinical trials sponsored by BMS/Celgene, EMD Serono, Novartis, Roche, and Sanofi; and has acted as site PI for multi-center trials funded by BMS/Celgene, EMD Serono, Novartis, Roche, and Sanofi Genzyme. MMS serves on the editorial board of Neurology, Multiple Sclerosis Journal, and Frontiers in Neurology; receives research support from the Dutch MS Research Foundation, Eurostars-EUREKA, Association pur la Recherche sur la Sclerose en Plaque, Amsterdam Neuroscience, MAGNIMS, and ZonMW (Vidi grant, project number 09150172010056); and has served as a consultant for or received research support from Atara Biotherapeutics, Biogen, Celgene/Bristol Meyers Squibb, EIP, Sanofi, MedDay, and Merck. NS receives research funding from the NIH, National MS Society, and Patient Centered Outcomes Research Institute. ATo has been supported by recent grants from the Medical Research Council (MR/S026088/1National Institute for Health and Care Research Biomedical Research Centre (541/CAP/OC/818837), and RoseTrees Trust (A1332 and PGL21/10079); speaker honoraria from Merck, Biomedia, Sereno Symposia International Foundation, Bayer, and At the Limits; was reimbursed for meeting expenses from Merck, Biogen Idec, and Novartis; and was the UK PI for two clinical trials sponsored by MEDDAY pharmaceutical company (MD1003 in optic neuropathy [MS-ON - NCT02220244] and progressive MS [MS-SPI2 - NCT02936037]). JW has research support from Biogen; is a consultant for BMS; and has been a speaker for Biogen, EMD Serono, and Sanofi. JS-G received compensation in the last 24 months for consulting services and speaking honoraria from BMS, Sanofi, Merck, and Roche; is scientific director of Revista de Neurología and member of the editorial committee of Multiple Sclerosis Journal, for which he receives an honorarium; and he has received research support from Fondo de Investigación en Salud (PI19/00950 and PI22/00750) from Instituto de Salud Carlos III, Spain. ATr is the MS Canada Research Chair; has received honoraria from Sanofi for membership in data monitoring committee and clinical trial steering committee and from Roche for clinical trial steering committee membership; and declares research funding from Roche, NIH, and MS Society of Canada. DO has received research support from the National Institutes of Health, National Multiple Sclerosis Society, Patient Centered Outcomes Research Institute, Race to Erase MS Foundation, Genentech, Genzyme, Bristol Myers Squibb, and Novartis; and declares consulting fees from Bristol Myers Squibb, Genentech/Roche, Novartis, and Contineum Therapeutics. AR serves on scientific advisory boards for Novartis, Sanofi, Synthetic MR, Roche, and Biogen; has received speaker honoraria from Bayer, Sanofi-Genzyme, Merck-Serono, Teva Pharmaceutical Industries, Novartis, Roche, Bristol-Myers and Biogen; is the CMO and co-founder of TensorMedical; and receives research support from Fondo de Investigación en Salud (PI19/00950 and PI22/01589) from Instituto de Salud Carlos III, Spain. All other authors declare no competing interests.

Acknowledgments

Daniel S Reich's contributions were made as part of his official duties as an NIH federal employee, are in compliance with agency policy requirements, and are considered Works of the US Government. However, the findings and conclusions presented in this paper are those of the author and do not necessarily reflect the views of the NIH or the US Department of Health and Human Services.

References

1 Montalban X, Lebrun-Frénay C, Oh J, et al. Diagnosis of multiple sclerosis: 2024 revisions of the McDonald criteria. *Lancet Neurol* 2025; **24:** 850–65.

2 Polman CH, Reingold SC, Banwell B, et al. Diagnostic criteria for multiple sclerosis: 2010 revisions to the McDonald criteria. *Ann Neurol* 2011; **69:** 292–302.

3 Filippi M, Rocca MA, Ciccarelli O, et al. MRI criteria for the diagnosis of multiple sclerosis: MAGNIMS consensus guidelines. *Lancet Neurol* 2016; **15:** 292–303.

4 Saidha S, Green AJ, Leocani L, et al. The use of optical coherence tomography and visual evoked potentials in the 2024 McDonald diagnostic criteria for multiple sclerosis. *Lancet Neurol* 2025; **24:** 880–92.

5 Wattjes MP, Ciccarelli O, Reich DS, et al. 2021 MAGNIMS-CMSC-NAIMS consensus recommendations on the use of MRI in patients with multiple sclerosis. *Lancet Neurol* 2021; **20:** 653–70.

6 Solomon AJ, Naismith RT, Cross AH. Misdiagnosis of multiple sclerosis: impact of the 2017 McDonald criteria on clinical practice. *Neurology* 2019; **92:** 26–33.

7 Bot JCJ, Barkhof F, Lycklama à Nijeholt G, et al. Differentiation of multiple sclerosis from other inflammatory disorders and cerebrovascular disease: value of spinal MR imaging. *Radiology* 2002; **223:** 46–56.

8 Hong J, Gaubert M, Lefort M, et al. Limited added value of systematic spinal cord MRI vs brain MRI alone to classify patients with MS as active or inactive during follow-up. *J Neurol* 2025; **272:** 316.

9 Ontaneda D, Sati P, Raza P, et al. Central vein sign: a diagnostic biomarker in multiple sclerosis (CAVS-MS) study protocol for a prospective multicenter trial. *Neuroimage Clin* 2021; **32:** 102834.

10 Traboulsee A, Li D. Addressing concerns regarding the use of gadolinium in a standardized MRI protocol for the diagnosis and follow-up of multiple sclerosis. *AJNR Am J Neuroradiol* 2016; **37:** E82–83.

11 Gulani V, Calamante F, Shellock FG, Kanal E, Reeder SB, and the International Society for Magnetic Resonance in Medicine. Gadolinium deposition in the brain: summary of evidence and recommendations. *Lancet Neurol* 2017; **16:** 564–70.

12 Sati P, Thomasson DM, Li N, et al. Rapid, high-resolution, whole-brain, susceptibility-based MRI of multiple sclerosis. *Mult Scler* 2014; **20:** 1464–70.

13 Sati P, George IC, Shea CD, Gaitán MI, Reich DS. FLAIR*: a combined MR contrast technique for visualizing white matter lesions and parenchymal veins. *Radiology* 2012; **265:** 926–32.

14 George IC, Sati P, Absinta M, et al. Clinical 3-tesla FLAIR* MRI improves diagnostic accuracy in multiple sclerosis. *Mult Scler* 2016; **22:** 1578–86.

15 Clarke MA, Pareto D, Pessini-Ferreira L, et al. Value of 3T susceptibility-weighted imaging in the diagnosis of multiple sclerosis. *AJNR Am J Neuroradiol* 2020; **41:** 1001–08.

16 Castellaro M, Tamanti A, Pisani AI, Pizzini FB, Crescenzo F, Calabrese M. The use of the central vein sign in the diagnosis of multiple sclerosis: a systematic review and meta-analysis. *Diagnostics* 2020; **10:** 1025.

17 Daboul L, O'Donnell CM, Cao Q, et al. Effect of GBCA use on detection and diagnostic performance of the central vein sign: evaluation using a 3-T FLAIR* sequence in patients with suspected multiple sclerosis. *AJR Am J Roentgenol* 2023; **220:** 115–25.

18 do Amaral LLF, Fragoso DC, Nunes RH, Littig IA, da Rocha AJ. Gadolinium-enhanced susceptibility-weighted imaging in multiple sclerosis: optimizing the recognition of active plaques for different MR imaging sequences. *AJNR Am J Neuroradiol* 2019; **40:** 614–19.

19 Geurts JJG, Roosendaal SD, Calabrese M, et al. Consensus recommendations for MS cortical lesion scoring using double inversion recovery MRI. *Neurology* 2011; **76:** 418–24.

20 Sethi V, Yousry TA, Muhlert N, et al. Improved detection of cortical MS lesions with phase-sensitive inversion recovery MRI. *J Neurol Neurosurg Psychiatry* 2012; **83:** 877–82.

21 Nelson F, Poonawalla A, Datta S, Wolinsky J, Narayana P. Is 3D MPRAGE better than the combination DIR/PSIR for cortical lesion detection at 3T MRI? *Mult Scler Relat Disord* 2014; **3:** 253–57.

22 Eisele P, Szabo K, Griebe M, et al. Reduced diffusion in a subset of acute MS lesions: a serial multiparametric MRI study. *AJNR Am J Neuroradiol* 2012; **33:** 1369–73.

23 Bot JCJ, Barkhof F. Spinal-cord MRI in multiple sclerosis: conventional and nonconventional MR techniques. *Neuroimaging Clin N Am* 2009; **19:** 81–99.

24 Hodel J, Outteryck O, Bocher AL, et al. Comparison of 3D double inversion recovery and 2D STIR FLAIR MR sequences for the imaging of optic neuritis: pilot study. *Eur Radiol* 2014; **24:** 3069–75.

25 Riederer I, Mühlau M, Hoshi MM, Zimmer C, Kleine JF. Detecting optic nerve lesions in clinically isolated syndrome and multiple sclerosis: double-inversion recovery magnetic resonance imaging in comparison with visually evoked potentials. *J Neurol* 2019; **266:** 148–56.

26 London F, Zéphir H, Hadhoum N, et al. Optic nerve double inversion recovery hypersignal in patients with clinically isolated syndrome is associated with asymptomatic gadolinium-enhanced lesion. *Mult Scler* 2019; **25:** 1888–95.

27 Solomon AJ, Bourdette DN, Cross AH, et al. The contemporary spectrum of multiple sclerosis misdiagnosis: a multicenter study. *Neurology* 2016; **87:** 1393–99.

28 Heinemann J, Yankov D, Solomon AJ, Rauer S, Wiendl H, Dersch R. McDonald criteria application by German neurologists suggests a need for further training. *Mult Scler Relat Disord* 2025; **94:** 106304.

29 Filippi M, Preziosa P, Banwell BL, et al. Assessment of lesions on magnetic resonance imaging in multiple sclerosis: practical guidelines. *Brain* 2019; **142:** 1858–75.

30 Ontaneda D, Raza PC, Mahajan KR, et al. Deep grey matter injury in multiple sclerosis: a NAIMS consensus statement. *Brain* 2021; **144:** 1974–84.

31 Lucchinetti CF, Gavrilova RH, Metz I, et al. Clinical and radiographic spectrum of pathologically confirmed tumefactive multiple sclerosis. *Brain* 2008; **131:** 1759–75.

32 Rovira À, Barkhof F. Multiple sclerosis and variants. In: Barkhof F, Jager R, Thurnher M, Rovira Cañellas A, eds. Clinical neuroradiology: the ESNR textbook. Cham: Springer International Publishing, 2018: 1–41.

33 Horowitz AL, Kaplan RD, Grewe G, White RT, Salberg LM. The ovoid lesion: a new MR observation in patients with multiple sclerosis. *AJNR Am J Neuroradiol* 1989; **10:** 303–05.

34 Calabrese M, Filippi M, Gallo P. Cortical lesions in multiple sclerosis. *Nat Rev Neurol* 2010; **6:** 438–44.

35 Rovira À, Sastre-Garriga J, Auger C, Rovira A. Idiopathic inflammatory demyelinating diseases of the brainstem. *Semin Ultrasound CT MR* 2013; **34:** 123–30.

36 Cotton F, Weiner H L, Jolesz F A, Guttmann C R G. MRI contrast uptake in new lesions in relapsing-remitting MS followed at weekly intervals. *Neurology* 2003; **60:** 640–46.

37 Masdeu JC, Quinto C, Olivera C, Tenner M, Leslie D, Visintainer P. Open-ring imaging sign: highly specific for atypical brain demyelination. *Neurology* 2000; **54:** 1427–33.

38 Gaitán MI, Shea CD, Evangelou IE, et al. Evolution of the blood–brain barrier in newly forming multiple sclerosis lesions. *Ann Neurol* 2011; **70:** 22–29.

39 Foster MA, Pontillo G, Davagnanam I, et al. Improving criteria for dissemination in space in multiple sclerosis by including additional regions. *Ann Clin Transl Neurol* 2024; **11:** 2572–82.

40 Tan IL, van Schijndel RA, Pouwels PJ, et al. MR venography of multiple sclerosis. *AJNR Am J Neuroradiol* 2000; **21:** 1039–42.

41 Sinnecker T, Clarke MA, Meier D, et al. Evaluation of the central vein sign as a diagnostic imaging biomarker in multiple sclerosis. *JAMA Neurol* 2019; **76:** 1446–56.

42 Suthiphosuwan S, Sati P, Guenette M, et al. The central vein sign in radiologically isolated syndrome. *AJNR Am J Neuroradiol* 2019; **40:** 776–83.

43 Boccia VD, Lapucci C, Cellerino M, et al. Evaluating the central vein sign in paediatric-onset multiple sclerosis: a case series study. *Mult Scler* 2023; **29:** 475–78.

44 Maggi P, Absinta M, Sati P, et al. The "central vein sign" in patients with diagnostic "red flags" for multiple sclerosis: a prospective multicenter 3T study. *Mult Scler* 2020; **26:** 421–32.

45 Sati P, Oh J, Constable RT, et al. The central vein sign and its clinical evaluation for the diagnosis of multiple sclerosis: a consensus statement from the North American Imaging in Multiple Sclerosis Cooperative. *Nat Rev Neurol* 2016; **12:** 714–22.

46 Bagnato F, Sati P, Hemond CC, et al. Imaging chronic active lesions in multiple sclerosis: a consensus statement. *Brain* 2024; **147:** 2913–33.

47 Suh CH, Kim SJ, Jung SC, Choi CG, Kim HS. The "Central Vein Sign" on T2*-weighted images as a diagnostic tool in multiple sclerosis: a systematic review and meta-analysis using individual patient data. *Sci Rep* 2019; **9:** 18188.

48 Daboul L, O'Donnell CM, Amin M, et al. A multicenter pilot study evaluating simplified central vein assessment for the diagnosis of multiple sclerosis. *Mult Scler* 2024; **30:** 25–34.

49 Absinta M, Sati P, Masuzzo F, et al. Association of chronic active multiple sclerosis lesions with disability in vivo. *JAMA Neurol* 2019; **76:** 1474–83.

50 Maggi P, Sati P, Nair G, et al. Paramagnetic rim lesions are specific to multiple sclerosis: an international multicenter 3T MRI study. *Ann Neurol* 2020; **88:** 1034–42.

51 Absinta M, Sati P, Schindler M, et al. Persistent 7-tesla phase rim predicts poor outcome in new multiple sclerosis patient lesions. *J Clin Invest* 2016; **126:** 2597–609.

52 Sacco S, Virupakshaiah A, Papinutto N, et al. Susceptibility-based imaging aids accurate distinction of pediatric-onset MS from myelin oligodendrocyte glycoprotein antibody-associated disease. *Mult Scler* 2023; **29:** 1736–47.

53 Oh J, Suthiphosuwan S, Sati P, et al. Cognitive impairment, the central vein sign, and paramagnetic rim lesions in RIS. *Mult Scler* 2021; **27:** 2199–208.

54 Absinta M, Maric D, Gharagozloo M, et al. A lymphocyte-microglia-astrocyte axis in chronic active multiple sclerosis. *Nature* 2021; **597:** 709–14.

55 Hemond CC, Reich DS, Dundamadappa SK. Paramagnetic rim lesions in multiple sclerosis: comparison of visualization at 1·5-T and 3-T MRI. *AJR Am J Roentgenol* 2022; **219:** 120–31.

56 Meaton I, Altokhis A, Allen CM, et al. Paramagnetic rims are a promising diagnostic imaging biomarker in multiple sclerosis. *Mult Scler* 2022; **28:** 2212–20.

57 Ramanathan S, Prelog K, Barnes EH, et al. Radiological differentiation of optic neuritis with myelin oligodendrocyte glycoprotein antibodies, aquaporin-4 antibodies, and multiple sclerosis. *Mult Scler* 2016; **22:** 470–82.

58 Dutra BG, da Rocha AJ, Nunes RH, Maia ACM. Neuromyelitis optica spectrum disorders: spectrum of MR imaging findings and their differential diagnosis. *Radiographics* 2018; **38:** 169–93.

59 Davion JB, Lopes R, Drumez É, et al. Asymptomatic optic nerve lesions: an underestimated cause of silent retinal atrophy in MS. *Neurology* 2020; **94:** e2468–78.

60 Sartoretti T, Sartoretti E, Rauch S, et al. How common is signal-intensity increase in optic nerve segments on 3D double inversion recovery sequences in visually asymptomatic patients with multiple sclerosis? *AJNR Am J Neuroradiol* 2017; **38:** 1748–53.

61 Biousse V, Danesh-Meyer HV, Saindane AM, Lamirel C, Newman NJ. Imaging of the optic nerve: technological advances and future prospects. *Lancet Neurol* 2022; **21:** 1135–50.

62 Dubey D, Pittock SJ, Krecke KN, et al. Clinical, radiologic, and prognostic features of myelitis associated with myelin oligodendrocyte glycoprotein autoantibody. *JAMA Neurol* 2019; **76:** 301–09.

63 Yonezu T, Ito S, Mori M, et al. "Bright spotty lesions" on spinal magnetic resonance imaging differentiate neuromyelitis optica from multiple sclerosis. *Mult Scler* 2014; **20:** 331–37.

64 Flanagan EP, Marsh RW, Weinshenker BG. Teaching neuroimages: "pancake-like" gadolinium enhancement suggests compressive myelopathy due to spondylosis. *Neurology* 2013; **80:** e229.

65 Li X, Krecke KN, Weinshenker BG, et al. Hemicord white matter enhancement and the croissant sign in cervical spondylotic myelopathy. *Neurology* 2023; **101:** 968–69.

66 Zalewski NL, Krecke KN, Weinshenker BG, et al. Central canal enhancement and the trident sign in spinal cord sarcoidosis. *Neurology* 2016; **87:** 743–44.

67 Prosperini L, Lucchini M, Ruggieri S, et al. Shift of multiple sclerosis onset towards older age. *J Neurol Neurosurg Psychiatry* 2022; **93:** jnnp-2022–329049.

68 Nyquist PA, Bilgel M, Gottesman R, et al. Age differences in periventricular and deep white matter lesions. *Neurobiol Aging* 2015; **36:** 1653–58.

69 Del Brutto OH, Mera RM, Costa AF, Silva P, Del Brutto VJ. Dawson fingers in older adults with cerebral small vessel disease: a population study. *Eur Neurol* 2020; **83:** 421–25.

70 Lapucci C, Saitta L, Bommarito G, et al. How much do periventricular lesions assist in distinguishing migraine with aura from CIS? *Neurology* 2019; **92:** e1739–44.

71 Absinta M, Rocca MA, Colombo B, et al. Patients with migraine do not have MRI-visible cortical lesions. *J Neurol* 2012; **259:** 2695–98.

72 Arrambide G, Tintore M, Auger C, et al. Lesion topographies in multiple sclerosis diagnosis: a reappraisal. *Neurology* 2017; **89:** 2351–56.

73 Filippi M, Preziosa P, Meani A, et al. Performance of the 2017 and 2010 revised McDonald criteria in predicting MS diagnosis after a clinically isolated syndrome: a MAGNIMS study. *Neurology* 2022; **98:** e1–14.

74 Cagol A, Cortese R, Barakovic M, et al. Diagnostic performance of cortical lesions and the central vein sign in multiple sclerosis. *JAMA Neurol* 2024; **81:** 143–53.

75 Geraldes R, Juryńczyk M, Dos Passos GR, et al. The role of pontine lesion location in differentiating multiple sclerosis from vascular risk factor-related small vessel disease. *Mult Scler* 2021; **27:** 968–72.

76 Guisset F, Lolli V, Bugli C, et al. The central vein sign in multiple sclerosis patients with vascular comorbidities. *Mult Scler* 2021; **27:** 1057–65.

77 Harrison KL, Gaudioso C, Levasseur VA, et al. Central vein sign in pediatric multiple sclerosis and myelin oligodendrocyte glycoprotein antibody-associated disease. *Pediatr Neurol* 2023; **146:** 21–25.

78 Menascu S, Halusková S, Pollak A, et al. Clinical correlation between disease progression and central vein sign in pediatric onset multiple sclerosis: a binational study. *Eur J Paediatr Neurol* 2024; **50:** 81–85.

79 Margoni M, Preziosa P, Storelli L, et al. Paramagnetic rim and core sign lesions in paediatric multiple sclerosis patients. *J Neurol Neurosurg Psychiatry* 2023; **94:** 873–76.

80 Micheletti L, Maldonado FR, Watal P, et al. Utility of paramagnetic rim lesions on 1·5-T susceptibility phase imaging for the diagnosis of pediatric multiple sclerosis. *Pediatr Radiol* 2022; **52:** 97–103.

81 Papp V, Magyari M, Aktas O, et al. Worldwide incidence and prevalence of neuromyelitis optica: a systematic review. *Neurology* 2021; **96:** 59–77.

82 Gaitán MI, Paday Formenti ME, Calandri I, et al. The central vein sign is present in most infratentorial multiple sclerosis plaques. *Mult Scler Relat Disord* 2022; **58:** 103484.

83 Abdel Ghany H, Karam-Allah A, Edward R, Abdel Naseer M, Hegazy MI. Sensitivity and specificity of central vein sign as a diagnostic biomarker in egyptian patients with multiple sclerosis. *Neuropsychiatr Dis Treat* 2022; **18:** 1985–92.

84 Scalfari A, Romualdi C, Nicholas RS, et al. The cortical damage, early relapses, and onset of the progressive phase in multiple sclerosis. *Neurology* 2018; **90:** e2107–18.

85 Matthews PM, Gupta D, Mittal D, et al. The association between brain volume loss and disability in multiple sclerosis: a systematic review. *Mult Scler Relat Disord* 2023; **74:** 104714.

86 Tintore M, Rovira A, Arrambide G, et al. Brainstem lesions in clinically isolated syndromes. *Neurology* 2010; **75:** 1933–38.

87 Galassi S, Prosperini L, Logoteta A, et al. A lesion topography-based approach to predict the outcomes of patients with multiple sclerosis treated with interferon beta. *Mult Scler Relat Disord* 2016; **8:** 99–106.

88 Ostini C, Bovis F, Disanto G, et al. Recurrence and prognostic value of asymptomatic spinal cord lesions in multiple sclerosis. *J Clin Med* 2021; **10:** 463.

89 Maggi P, Sati P, Nair G, et al. Paramagnetic rim lesions are specific to multiple sclerosis: an international multicenter 3T MRI study. *Ann Neurol* 2020; **88:** 1034–42.

90 Altokhis AI, Hibbert AM, Allen CM, et al. Longitudinal clinical study of patients with iron rim lesions in multiple sclerosis. *Mult Scler* 2022; **28:** 2202–11.

91 Arrambide G, Rovira A, Sastre-Garriga J, et al. Spinal cord lesions: a modest contributor to diagnosis in clinically isolated syndromes but a relevant prognostic factor. *Mult Scler* 2018; **24:** 301–12.

92 Brownlee WJ, Altmann DR, Prados F, et al. Early imaging predictors of long-term outcomes in relapse-onset multiple sclerosis. *Brain* 2019; **142:** 2276–87.

93 Mallucci G, Ferraro OE, Trojano M, et al. Early prediction of unfavorable evolution after a first clinical episode suggestive of multiple sclerosis: the EUMUS score. *J Neurol* 2024; **271:** 3496–505.

94 Kappos L, Moeri D, Radue EW, et al. Predictive value of gadolinium-enhanced magnetic resonance imaging for relapse rate and changes in disability or impairment in multiple sclerosis: a meta-analysis. *Lancet* 1999; **353:** 964–69.

95 Eshaghi A, Prados F, Brownlee WJ, et al. Deep gray matter volume loss drives disability worsening in multiple sclerosis. *Ann Neurol* 2018; **83:** 210–22.

96 Uher T, Krasensky J, Malpas C, et al. Evolution of brain volume loss rates in early stages of multiple sclerosis. *Neurol Neuroimmunol Neuroinflamm* 2021; **8:** e979.

97 Azevedo CJ, Overton E, Khadka S, et al. Early CNS neurodegeneration in radiologically isolated syndrome. *Neurol Neuroimmunol Neuroinflamm* 2015; **2:** e102.

98 Ruggieri S, Prosperini L, Al-Araji S, et al. Assessing treatment response to oral drugs for multiple sclerosis in real-world setting: a MAGNIMS Study. *J Neurol Neurosurg Psychiatry* 2024; **95:** 142–50.

99 Kunchok A, Lechner-Scott J, Granella F, et al. Prediction of on-treatment disability worsening in RRMS with the MAGNIMS score. *Mult Scler* 2021; **27:** 695–705.

100 Ruggieri S, Prosperini L, Petracca M, et al. The added value of spinal cord lesions to disability accrual in multiple sclerosis. *J Neurol* 2023; **270:** 4995–5003.

101 Dickerson E, Davenport MS, Syed F, et al. effect of template reporting of brain MRIs for multiple sclerosis on report thoroughness and neurologist-rated quality: results of a Prospective Quality Improvement Project. *J Am Coll Radiol* 2017; **14:** 371–79.e1.

102 Lee JK, Bermel R, Bullen J, Ruggieri P, Jones SE. Structured reporting in multiple sclerosis reduces interpretation time. *Acad Radiol* 2021; **28:** 1733–38.

103 Mendelsohn Z, Pemberton HG, Gray J, et al. Commercial volumetric MRI reporting tools in multiple sclerosis: a systematic review of the evidence. *Neuroradiology* 2023; **65:** 5–24.

104 Lim TR, Suthiphosuwan S, Micieli J, et al. Low-field (64mT) portable MRI for rapid point-of-care diagnosis of DIS in patients presenting with optic neuritis. *AJNR Am J Neuroradiol* 2024; **45:** 1819–25.

Copyright © 2025 Elsevier Ltd. All rights reserved, including those for text and data mining, AI training, and similar technologies.